

SUCCESSFUL TREATMENT OF AN END-STAGE KIDNEY DISEASE PATIENT PRESENTING WITH SEVERE COVID-19 DISEASE USING ENHANCED CYTOKINE REMOVAL WITH HAEMOADSORPTION THERAPY IN ADDITION TO STANDARD MANAGEMENT

Esther Zhao Zhi Tan¹, Hin Seng Wong^{1,2}

¹ Department of Nephrology, Selayang Hospital, Selangor, Malaysia

² Department of Clinical Research, Selayang Hospital, Selangor, Malaysia

ABSTRACT

End-stage kidney disease patients with severe COVID-19 disease have a higher mortality rate as compared to those with no comorbidities. Here we report a case of endstage renal disease patient on regular haemodialysis presenting with severe COVID-19 disease and subsequently developing septic shock during the inpatient stay. In addition to standard management with steroids because of the hypoxia, this patient also received antibiotics and haemoadsorption therapy to aid cytokine removal. There are limited data

on the use of haemoadsorption in endstage renal disease patients with COVID-19 disease. This patient survived to discharge without the need for supplemental oxygen. In conclusion, combined therapeutic modalities are a possible promising treatment for severe COVID-19 infection in endstage renal disease patients.

Keywords: COVID-19, End-stage kidney disease, haemoadsorption therapy

INTRODUCTION

In December 2019, the novel coronavirus disease 2019 (COVID-19), emerged in China and spread across the world.¹ Patient may present with a range of symptoms such as fever, cough and fatigue but elderly patients and those with comorbidities are at a higher risk for severe forms of the disease.¹ Extracorporeal blood purification has been proven to effectively remove the released inflammatory cytokines in various conditions with hyper inflammation, hemophagocytic lymphohistiocytosis, intoxication, sepsis, and others.² Here we report the case of a patient with

COVID-19 who benefited from haemoadsorption (HA). HA 330 cartridges contain neutro-macroporous resin adsorbing beads made of styrene-divinylbenzene copolymer and these cartridges can remove cytokines, complements, free haemoglobin thus improving oxygenation and attenuating lung injury.³ The recommended treatment duration is 2 to 2.5 hours but treatment duration can be prolonged depending on other hybrid therapies.³

CASE REPORT AND PRESENTATION

A 41-years old male with end-stage kidney disease (ESKD) on regular haemodialysis (HD) for the past 5 years via right brachiocephalic fistula presented to the emergency department (ED) with a history of fever, cough and worsening shortness of breath. He developed symptoms of fever after his first dose of COVID-19 vaccination 15 days before presentation. His last HD was 3 days before the presentation. His nasal swab Polymerase Chain Reaction (PCR) for Severe Acute Respiratory Syndrome

*Correspondence: Esther Zhao Zhi Tan
Department of Nephrology,
Selayang Hospital
Lebuhraya Selayang-Kepong,
68100 Batu Caves,
Selangor, Malaysia
Email: esthertzz@gmail.com



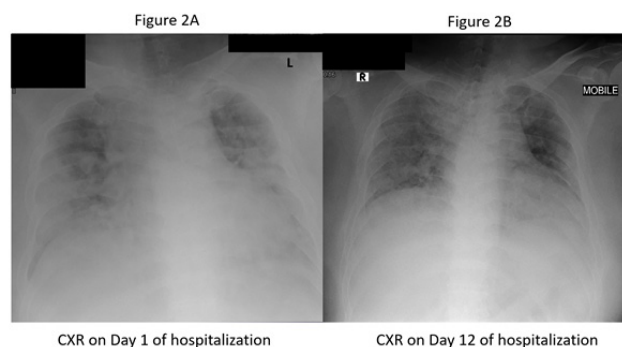
Coronavirus 2 (SARS-CoV-2) was positive with a cycle threshold (CT) value of 17. He was a chronic smoker, obese (body weight 120kg), and had hypertension. On presentation (Day 1 of hospitalization), he had an oxygen saturation of 30% on room air (RA), 60% on reservoir bag-mask (HFM) (15L) and 95% on High Flow Nasal Cannula Oxygen (HFNC) (60L). Figure 2A shows the patient's chest X-ray (CXR) on presentation to ED. He underwent urgent HD with ultrafiltration (UF) of 2.5 litres. Post HD, he was admitted to our nephrology ward for further management.

Laboratory results at the emergency department revealed Haemoglobin 11.8g/dL, White Blood Count $13.45 \times 10^3/\mu\text{L}$ with absolute neutrophil counts of $11.1 \times 10^3/\mu\text{L}$ (normal range $2.0\text{--}7.0 \times 10^3/\mu\text{L}$) and lymphocyte counts of $1.2 \times 10^3/\mu\text{L}$ (normal range $1.0\text{--}3.0 \times 10^3/\mu\text{L}$). His Sodium level was 124 mmol/L, Potassium 3.9 mmol/L, Urea 27.7 mmol/L, Creatinine 2,034 $\mu\text{mol/L}$, Alanine Aminotransferase (ALT) 101 U/L and Aspartate Aminotransferase (AST) 209 U/L (normal range 0-31). His creatine kinase (CK) level was 19,104 U/L, lactate dehydrogenase (LDH) 1,513 U/L with C-reactive protein (CRP) of 26.44 mg/dL. His recent Hepatitis B surface antigen and Anti HCV Antibodies tests were negative.

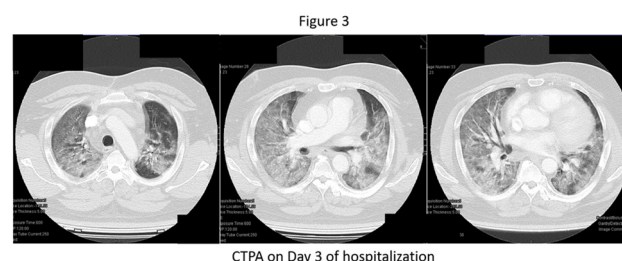
Table 1 summarises relevant laboratory tests on patient's initial presentation to the hospital and their reference range.

Test	On presentation	Reference Range
CRP, mg/dL	26.44	0-0.5, mg/dL
WBC, $10^3/\mu\text{L}$	13.45	4.0-10.0, $10^3/\mu\text{L}$
Hemoglobin, g/dL	11.8	13-17 g/dL
Platelets, $10^3/\mu\text{L}$	181	150-410, $10^3/\mu\text{L}$
Creatine Kinase, U/L	19,104	25-170, U/L
Lactate dehydrogenase, U/L	1,513	140-271, U/L
Procalcitonin, ng/mL	9.29	0-0.5 ng/mL
Urea, mmol/L	27.7	1.7-8.3, mmol/L
Creatinine, $\mu\text{mol/L}$	2,034	53-106, $\mu\text{mol/L}$
Albumin, g/L	42	35-50, g/L
Alanine Transaminase, U/L	101	0-43, U/L
Total Bilirubin, $\mu\text{mol/L}$	12	5-21, $\mu\text{mol/L}$

He was initiated on intravenous (IV) Dexamethasone 12mg once daily, oral pantoprazole and subcutaneous heparin for venous thromboembolism prophylaxis.



His D dimer was positive hence a computed tomography pulmonary angiogram (CTPA) was done on day 3 of hospitalization which did not show any evidence of pulmonary embolism. The CTPA (Figure 3 images) showed ground glass densities with a crazy-paving pattern at the central and peripheral distribution of both lung fields. There was no pneumothorax or pneumomediastinum seen. Features in the lungs on the CTPA were consistent with severe COVID-19 infection with more than 75% lung involvement with organizing pneumonia.



On day 5 of hospitalisation, his oxygen saturation worsened to 90% on 60L HFNC oxygen. He has initiated on IV Methylprednisolone 250mg once daily for 3 days. Despite the improvement in C-reactive protein levels (CRP) (see Table 2), his oxygenation requirements remained high and he was still dependent on High Flow Nasal Cannula 60L. Hence, on day 9 of hospitalization, he was treated with concomitant haemoadsorption (HA) therapy during his regular HD sessions with HA330 cartridge, Jafron Biomedical Co., Zhuhai, China. After one session of haemoadsorption therapy, oxygenation improved and he tolerated a face mask (FM) 8L/min with oxygen saturation of 98%. On room air, his oxygen saturation was 83%. On day 12 of hospitalization, his oxygen saturation was 95% on nasal prong (NP) 3L/min. He developed hypotension with BP of 80/40 mmHg and heart rate of 115 bpm (regular). He was resuscitated with 500mls of 0.9%

sodium chloride and repeated BP was 105/64 mmHg. A triple lumen catheter was inserted via the right femoral vein (ultrasound-guided). Blood cultures were obtained. He was treated with IV Cefepime and intravenous noradrenaline infusion. His dialysis therapy was modified to Sustained Low Efficiency Daily Dialysis (SLEDD) with concomitant haemoadsorption (HA).

Figure 2B shows his Chest X-ray post 2 sessions of haemoadsorption treatment.

On day 13 of hospitalization, he underwent another session of SLEDD with haemoadsorption.

The next day, his blood cultures grew gram-positive cocci and IV vancomycin was added. BP improved to 193/92 mmHg hence intravenous noradrenaline was discontinued. His oxygen saturation was 95% on NP 3L/min.

On day 19 of hospitalization, his oxygen saturation improved to 94% on room air. The blood cultures report was finalized showing mixed growth and he completed a total of 10 days IV cefepime and 8 days of IV Vancomycin. He was discharged home after 22 days of hospitalization with tapering dose of prednisolone and respiratory physician follow-up.

Table 2 summarises patient's progress and events during the course of his hospitalization.

Days of hospitalization	1	3	5	7
Oxygen saturation	30% on room air (RA), 60% on HFM 15L, 95% on HFNC 60L	96% on HFNC 60L	90% on HFNC 60L	95% on HFNC 60L
Steroid dose	IV Dexamethasone 12mg OD	IV Dexamethasone 12mg OD	IV Methylprednisolone 250mg OD	IV Methylprednisolone 250mg OD
HD/HA	HD UF 2.5L (done during early morning of Day 2)	-	HD UF 1.5L	HD UF 2L
Events	CXR	CTPA	-	-
Antibiotics	-	-	-	-
Laboratory Results	WCC $13.45 \times 10^3/\mu\text{L}$ (Absolute lymphocyte 1.2) Hb 11.8 g/dL Platelets 181 ALT 101 U/L AST 209 U/L CK 19,104 U/L LDH 1,513 U/L CRP 26.44 mg/dL Urea 27.7 mmol/L Na 124 mmol/L K 3.9 mmol/L Creatinine 2034 $\mu\text{mol/L}$ Albumin 42 g/L	D dimer positive 4.81 mcg/mL	WCC $9 \times 10^3/\mu\text{L}$ Hb 11 g/dL Platelets 248 ALT 65.4 U/L CRP 7.15 mg/dL Urea 54.6 mmol/L Na 134 mmol/L K 4.4 mmol/L Creatinine 2223 $\mu\text{mol/L}$ Albumin 34.8 g/L Procalcitonin 9.29 ng/mL	WCC $8.05 \times 10^3/\mu\text{L}$ Hb 10.8 g/dL Platelets 303 ALT 144 U/L Urea 57.9 mmol/L Na 132 mmol/L K 4.6 mmol/L Creatinine 1925 $\mu\text{mol/L}$ Albumin 34.9 g/L

Days of hospitalization	9	10	11
Oxygen saturation	98% on HFNC 60L	98% on FM 8L	92% on FM 5L, 83% on RA
Steroid dose	IV Dexamethasone 20mg OD	IV Dexamethasone 20mg OD	IV Dexamethasone 20mg OD
HD/HA	HD UF 1.5L + HA 330	-	-
Events	-	-	-
Antibiotics	-	-	-
Laboratory Results	WCC $7.68 \times 10^3/\mu\text{L}$ Hb 10.7 g/dL Platelets 290 Urea 68.6 mmol/L Na 131 mmol/L K 5 mmol/L Creatinine 1786 $\mu\text{mol/L}$ Albumin 33.3g/L		



Days of hospitalization	12	13	14
Oxygen saturation	95% on NP 3L	94% on NP 3L	95% on NP 3L
Steroid dose	IV Dexamethasone 16mg OD	IV Dexamethasone 16mg OD	IV Dexamethasone 16mg OD
HD/HA	SLEDD UF 1L +HA 330	SLEDD UF 1L + HA 330	-
Events	<ul style="list-style-type: none"> CXR done Hypotension- Fluid resuscitated IV Noradrenaline infusion started via triple lumen inserted into right femoral vein 	-	<ul style="list-style-type: none"> Blood cultures grew gram positive cocci. IV Noradrenaline infusion discontinued.
Antibiotics	IV Cefepime	IV Cefepime	IV Cefepime IV Vancomycin
Laboratory Results	WCC $44.67 \times 10^3/\mu\text{L}$ Hb 10.5 g/dL Platelets 296 ALT 69 U/L CK 1305 U/L Urea 73.3 mmol/L Na 129 mmol/L K 5.8 mmol/L Creatinine 1305 $\mu\text{mol/L}$ Albumin 30.1g/L	Procalcitonin 11.83 ng/mL	WCC $9.7 \times 10^3/\mu\text{L}$ Hb 9.2 g/dL Platelets 202 ALT 42.3 U/L CK 244 U/L CRP 24.62 mg/dL

Days of hospitalization	15	16	19
Oxygen saturation	96% on NP 3L, 92% on RA	94% on NP 3L, 81% on RA	94% on RA
Steroid dose	Prednisolone 60mg OD	Prednisolone 60mg OD	Prednisolone 55mg OD
HD/HA	-	HD UF 3L	HD UF 3.5L
Events	-	-	-
Antibiotics	IV Cefepime IV Vancomycin	IV Cefepime IV Vancomycin	IV Cefepime IV Vancomycin
Laboratory Results		WCC $9.92 \times 10^3/\mu\text{L}$ Hb 8.5 g/dL Platelets 185 ALT 31.6 U/L Urea 66.8 mmol/L Na 132 mmol/L K 6.0 mmol/L Creatinine 1356 $\mu\text{mol/L}$ Albumin 31.4g/L	WCC $17.2 \times 10^3/\mu\text{L}$ Hb 8.7 g/dL Platelets 139 ALT 50.6 U/L CRP 1.54 mg/dL Urea 71.9 mmol/L Na 130 mmol/L K 5.7 mmol/L Creatinine 1354 $\mu\text{mol/L}$ Albumin 32.3g/L

Days of hospitalization	20	21	22
Oxygen saturation	90% on RA		94% on RA
Steroid dose	Prednisolone 55mg OD	Prednisolone 40mg OD	Prednisolone 40mg OD with tapering dose every 3 days
HD/HA		HD UF 2.5L	-
Events		USS Doppler and Dilution USS done – no recirculation	Discharged with respiratory physician followup as outpatient
Antibiotics	IV Cefepime IV Vancomycin	IV Cefepime IV Vancomycin	-
Laboratory Results	-	-	-



DISCUSSION

Amongst hospitalized patients with COVID-19, mortality risk was increased in patients with ESKD compared to that in the general population.⁴ The mortality rates amongst endstage kidney disease patients on dialysis hospitalised for COVID-19 infection was reported to be between 13.3% to 42.1%.⁴ In a cross-sectional study, it was noted that the mortality rate was significantly lower in patients who received haemoadsorption without having mechanical ventilation.¹ In those who required mechanical ventilation, the duration of mechanical ventilation was lower when haemoadsorption was initiated prior to needing mechanical ventilation.¹ Another promising finding was that the PaO₂/FiO₂ ratio significantly increased in all patients after hemoperfusion resulting in improvement in oxygenation.¹ This patient's presentation was unusual as he had symptoms almost 14 days before presentation. His PCR test was positive 3 days prior to presentation. His condition was ill at presentation with severe hypoxia, raised inflammatory markers and elevated LDH and CRP levels. He was probably fluid overloaded as well having missed one session of his usual HD treatment. At presentation, this patient had liver injury (as documented by the raised liver enzymes and LDH levels) as well as probable skeletal muscle injury as documented by the elevated creatine kinase (CK) levels.

In an early study from Wuhan, skeletal muscle injury (defined as patient having skeletal muscle pain and elevated serum CK greater than 200 U/L) appears to be significantly more frequent in severe COVID-19 compared to less severe diseases (19.3% versus 4.8%).⁵ The receptor angiotensin-converting enzyme 2 (ACE2) was identified as the functional receptor for SARS-CoV-2 and this receptor is present in multiple human organs including the skeletal muscles hence it has been postulated that myocytes are also susceptible to direct muscle invasion by SARS-CoV-2.⁵

For this patient, the use of steroids likely helped with the initial early phase of acute respiratory distress syndrome (ARDS) as the CRP level appears to improve. However, despite treatment with high dose steroids and haemodialysis with ultrafiltration, his oxygen requirement remained high and hence haemoadsorption treatment was added to his usual haemodialysis session. The patient subsequently developed septic shock due to bacterial infection on Day 12 of hospitalization and the haemoadsorption treatment during that period could have been beneficial. There was a gradual decline in haemoglobin levels and an increase in urea levels during his inpatient stay but there was no overt clinical evidence of gastrointestinal bleed. As this patient was admitted to the hospital during the peak of the pandemic

and due to the limitation of services, he did not undergo further endoscopic examination given no clinical evidence of overt bleeding and he remained haemodynamically stable. An ultrasound doppler and ultrasound dilution test was done for the patient's fistula which did not show any recirculation hence the high urea was attributed to the high dose steroids used. This patient's Chest X-ray appeared to have improved slightly after the use of steroids, two applications of haemoadsorption therapy and a few haemodialysis sessions with ultrafiltration. He was discharged home well without the need for supplemental oxygen therapy.

CONCLUSION

The application of haemoadsorption therapy in addition to standard management in this patient may have been beneficial in terms of cytokine removal during sepsis. It is unclear whether the haemoadsorption prevented the progression of the disease to severe ARDS as he also had concomitant haemodialysis with ultrafiltration which may have improved his oxygenation. Ultimately, this patient did not require mechanical ventilation and was discharged home not requiring any supplemental oxygen therapy.

References

1. Abbasi S, Naderi Z, Amra B et al. Hemoperfusion in patients with severe COVID-19 respiratory failure, lifesaving or not? *Journal of Research in Medical Sciences* May 2021 DOI:10.4103/jrms.JRMS_1122_20
2. Napp CL, Bauersachs J. Extracorporeal Hemoadsorption: An option for COVID-19 associated cytokine storm syndrome. *Shock* 2020 Nov;54(5):700-701. DOI:10.1097/SHK.0000000000001568
3. Ankawi G, Fan W, Montin DP et al. A New Series of Sorbent Devices for Multiple Clinical Purposes: Current Evidence and Future Directions. *Blood Purif* 2019;47:94-100. DOI:10.1159/000493523
4. Ng JH, Hirsch JS, Wanchoo R et al. Outcomes of patients with end-stage kidney disease hospitalized with COVID-19. *Kidney Int.* 2020 Dec;98(6):1530-1539. DOI: 10.1016/j.kint.2020.07.030. Epub 2020 Aug 15.
5. Orsucci D, Trezzi M, Anichini R et al. Increased creatine kinase may predict a worse COVID-19 outcome. *J. Clin. Med* 2021, 10, 1734. <https://doi.org/10.3390/jcm10081734>.